




Tháp Bánh Ít, huyện Tuy Phước, tỉnh Bình Định













Tổn thương thần kinh trụ (Ulnar nerve injury)

Hồ Quang Hưng

16/4/2012

Anatomy of ulnar nerve

3 vị trí chèn ép hay gập:

1. Rãnh trụ ở trong khuỷu

2. Kênh Guyon ở cổ tay

3. Rãnh cổ C8, N1

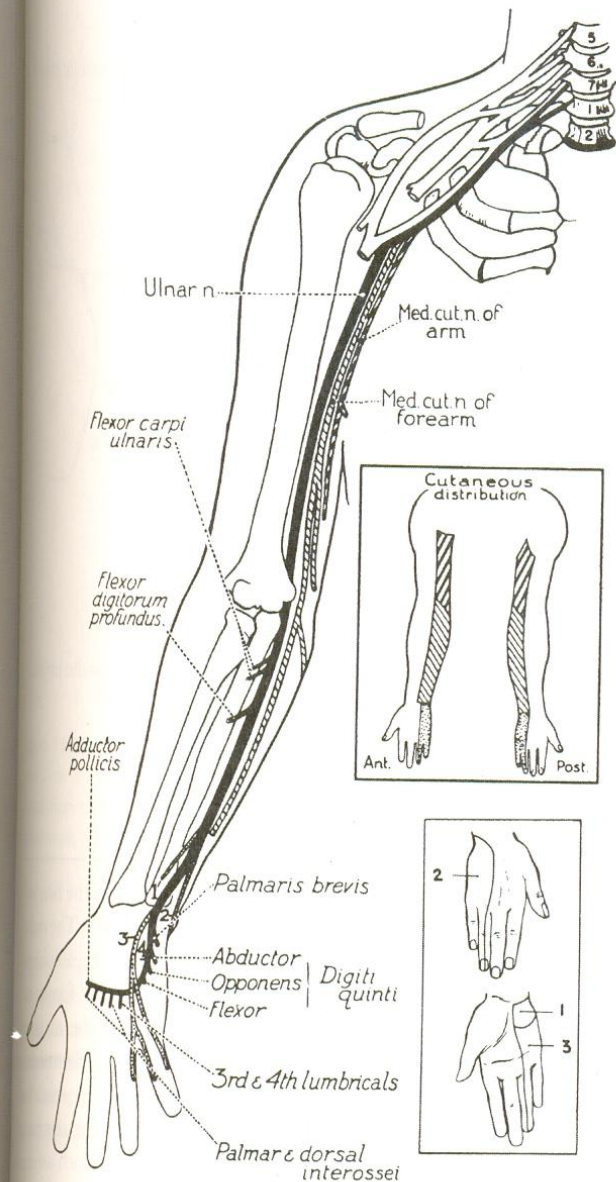
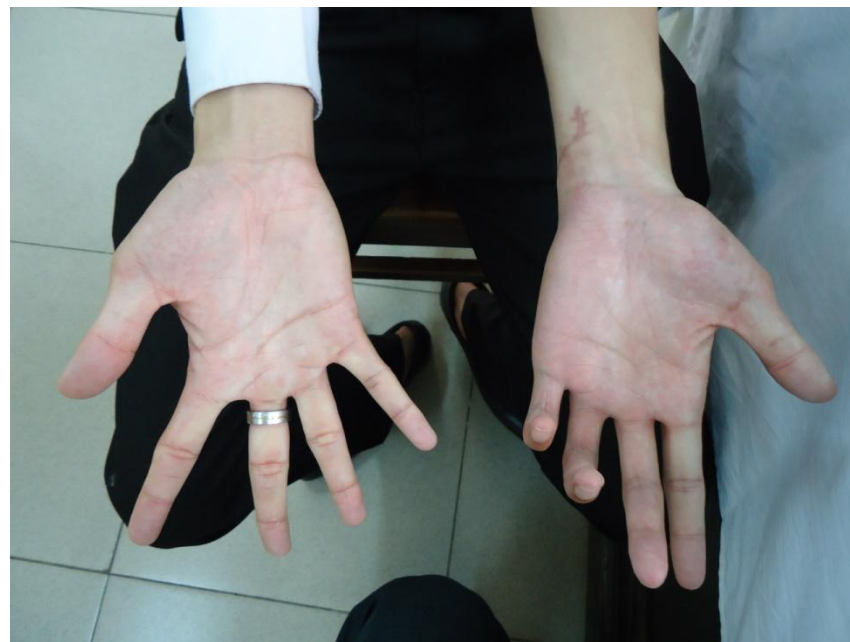
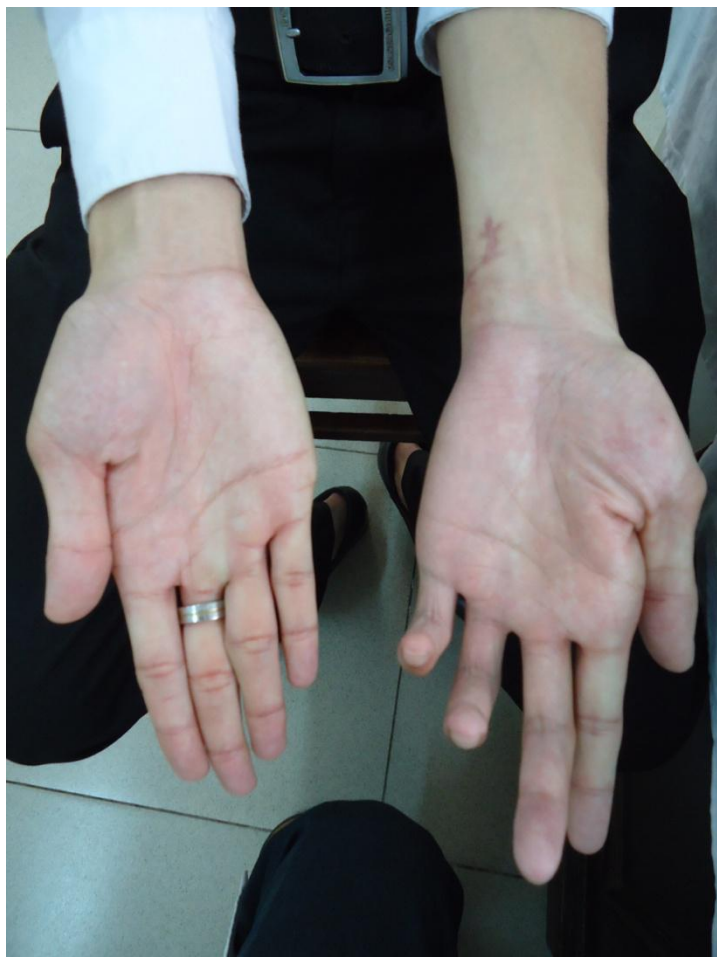
Figure 12-26 Schematic of the ulnar nerve. (From Haymaker W, Woodhall B: Peripheral nerve injuries: principles of diagnosis, Philadelphia, 1953, Saunders.)

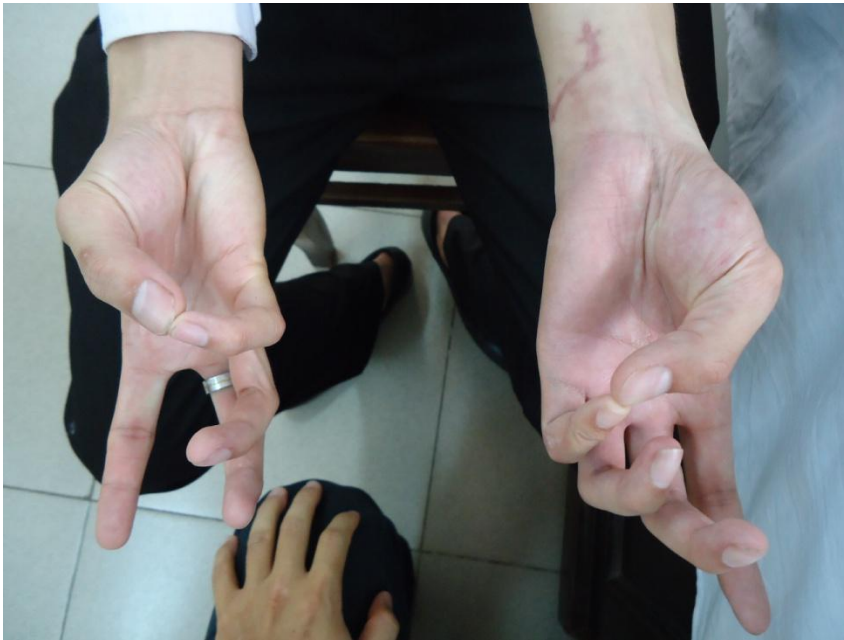Male, 21 ys, operated 4 months ago



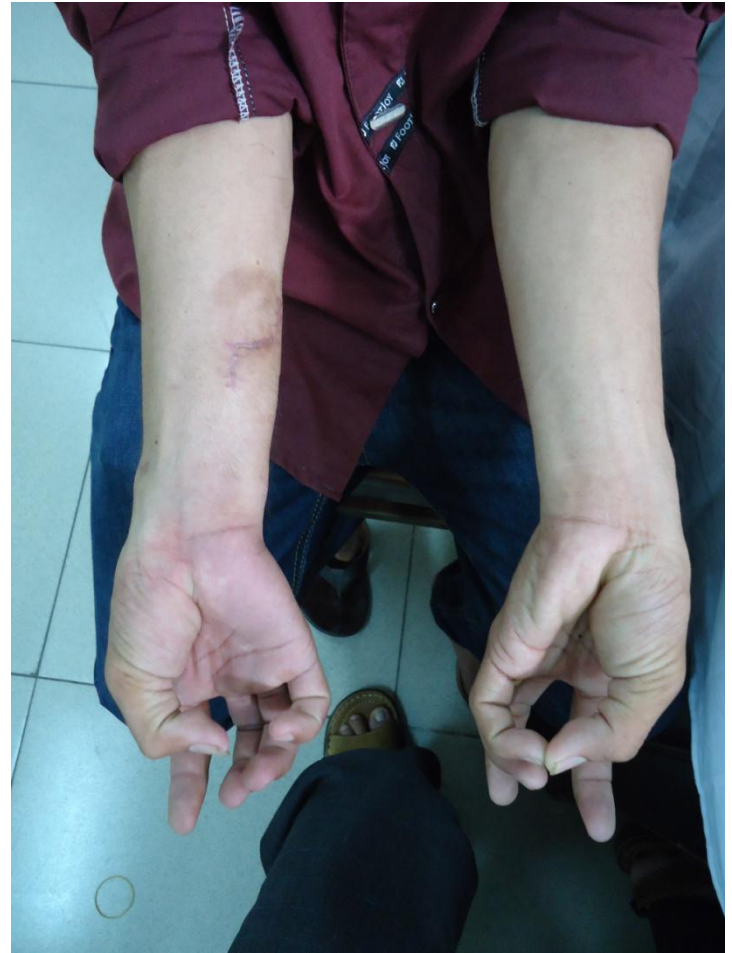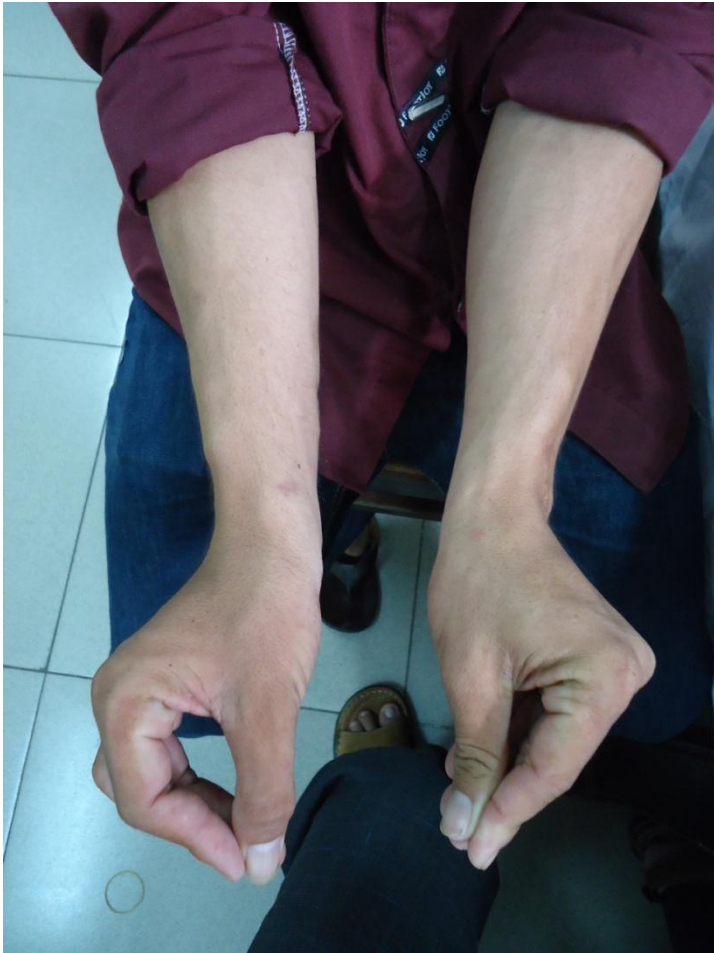Froment's sign (Adduction of thumb)



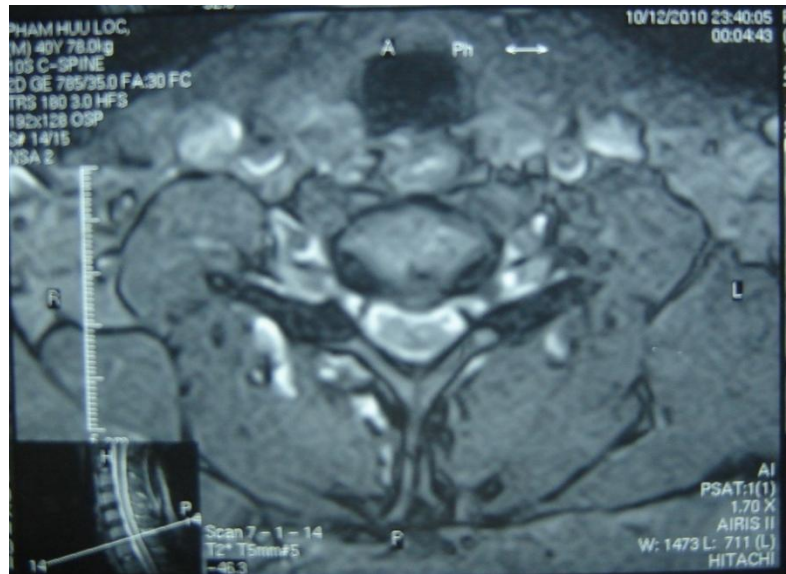
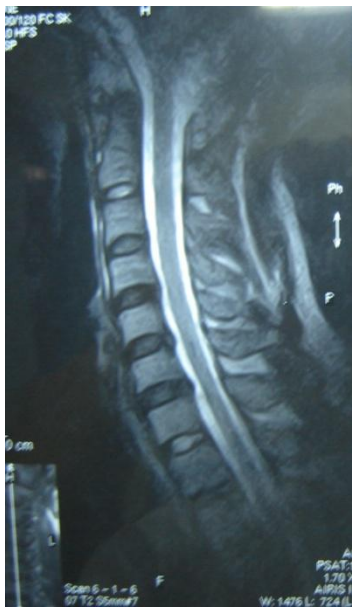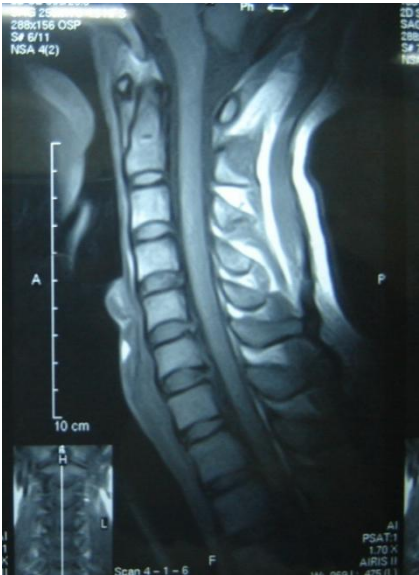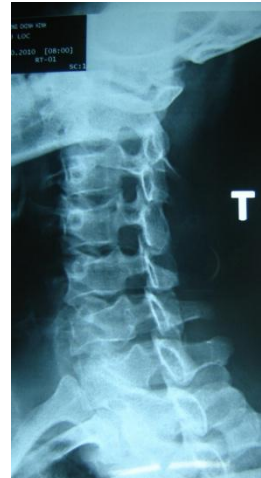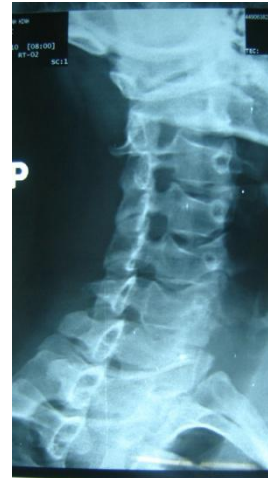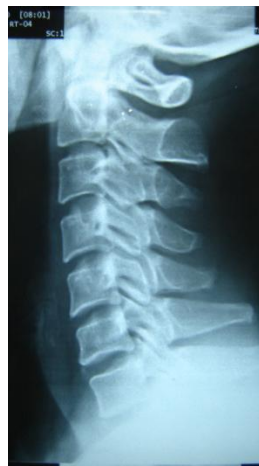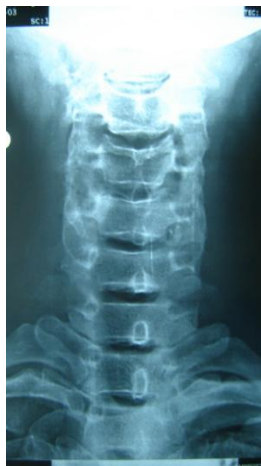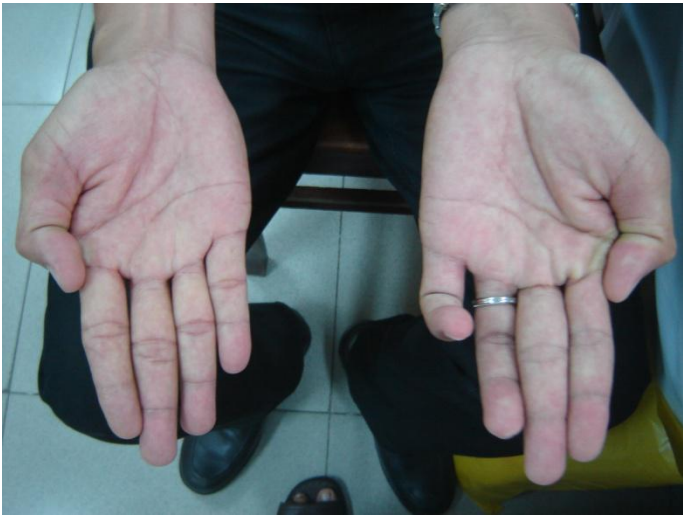Đôi ngón út (opposition)



Male, 20 ys, having operation 1 month ago



Male, 40ys. Neck pain radiating to left arm



Female, 36ys. Elbow injury 2 months ago.

