

Case report

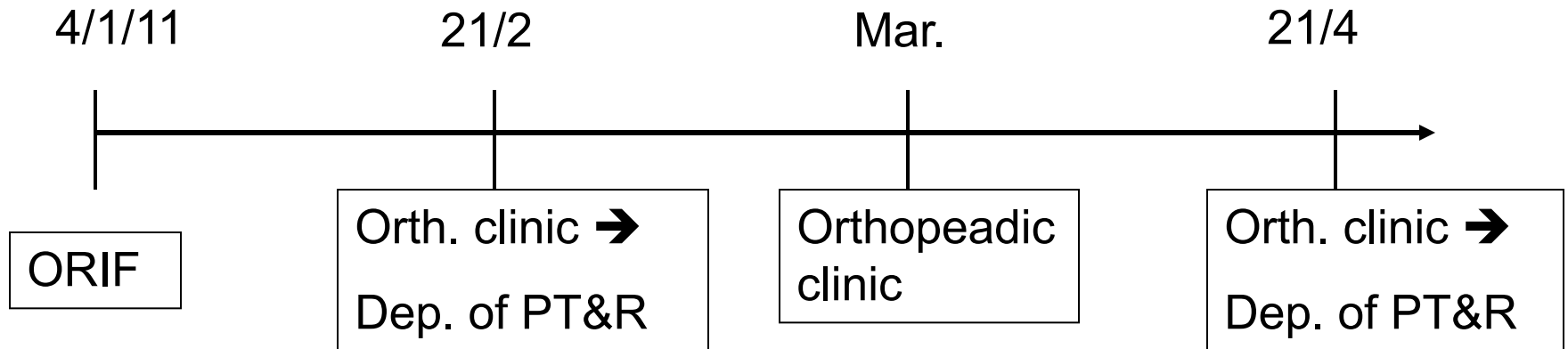
Restoration of knee ROM: do not ignore the extension

Hồ Quang Hưng

17/5/2011

History and evaluation

- A 24-year-old female, living in Vung Tau

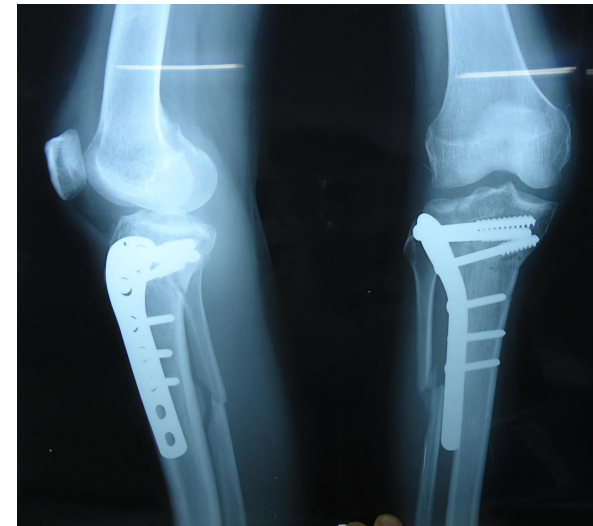
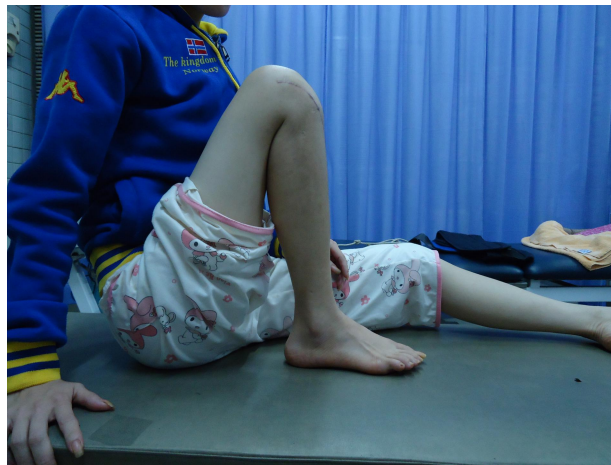
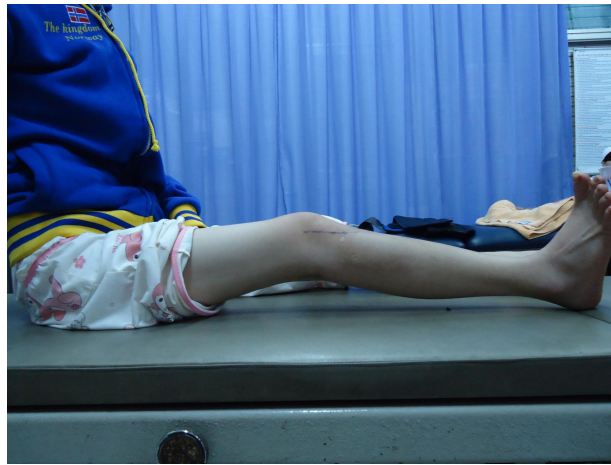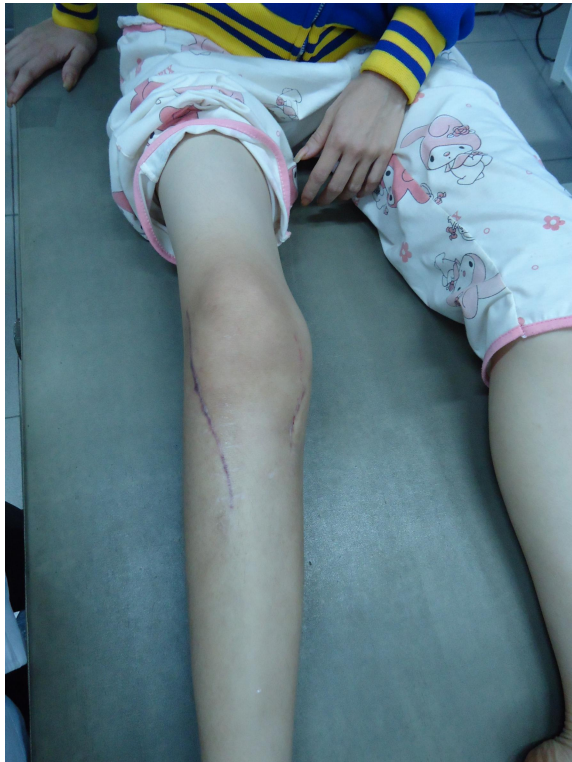Light swelling
ROM: (20⁰-60⁰)

No swelling
Passive E = -20⁰
Complete flexion
Muscle weakness
Minimal WB

ORIF (open reduction and internal fixation)

Evaluation at 21/4/2011



In opposite of flexion, extension has poorly improved

Efficacy of home exercise program

- Actual condition:
 - Refer to local service if possible
- Number of exercises:
 - Pay attention to the important one.
- Interval of visit
- Learning style: visual, auditory and tactile

Thank you for your attention!

Ý kiến người nghe

- Yếu cơ tứ đầu góp phần gây thiếu duỗi thụ động
- Mâm chày lún phải chăng do chổng chân sớm?
- Hướng dẫn trượt khớp duỗi gối ở nhà
- Trượt khớp có ảnh hưởng KHX không?