

PERIPHERAL NERVE INJURY

Hồ Quang Hưng

5/11/2010

Peripheral nervous system

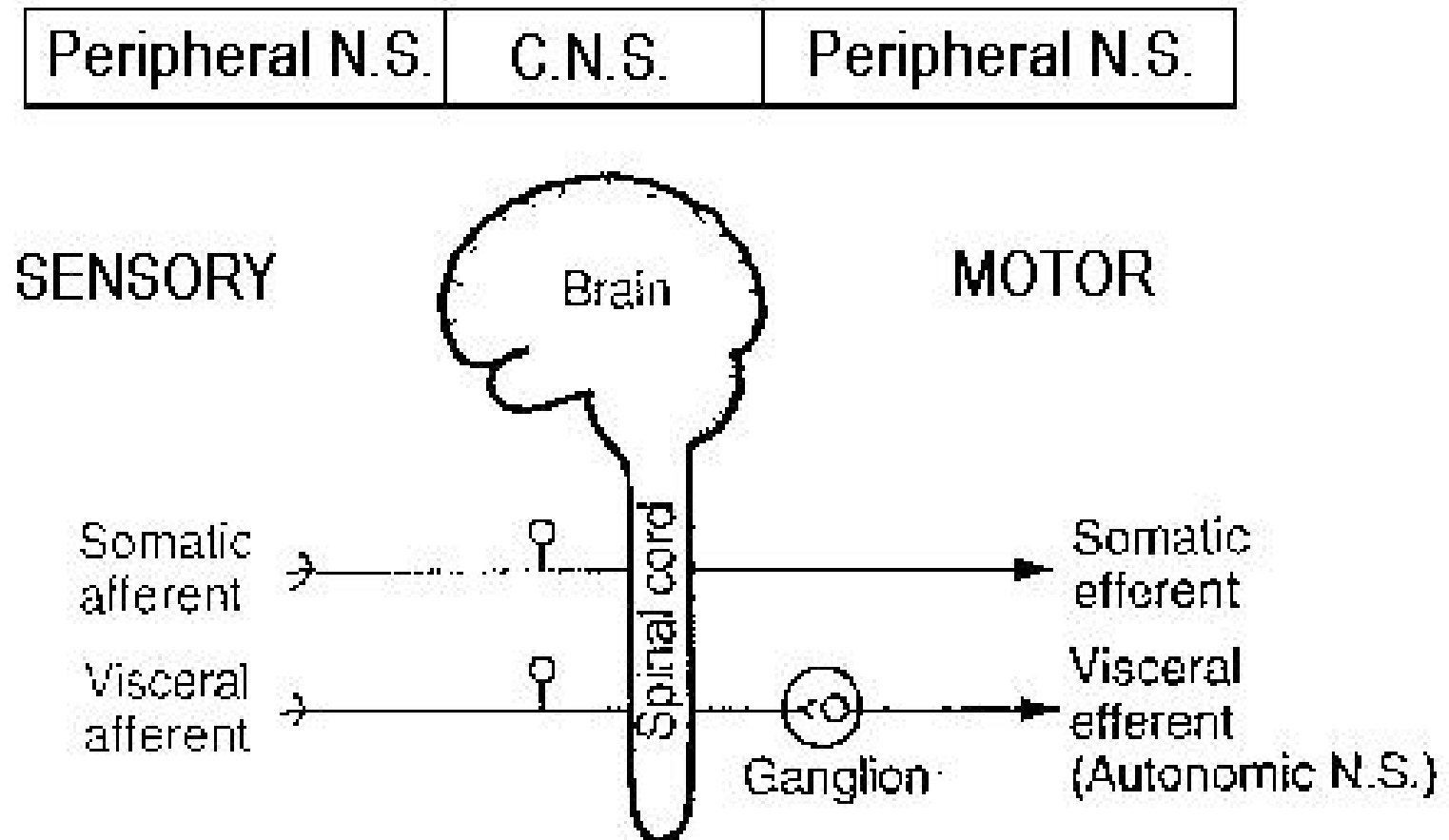
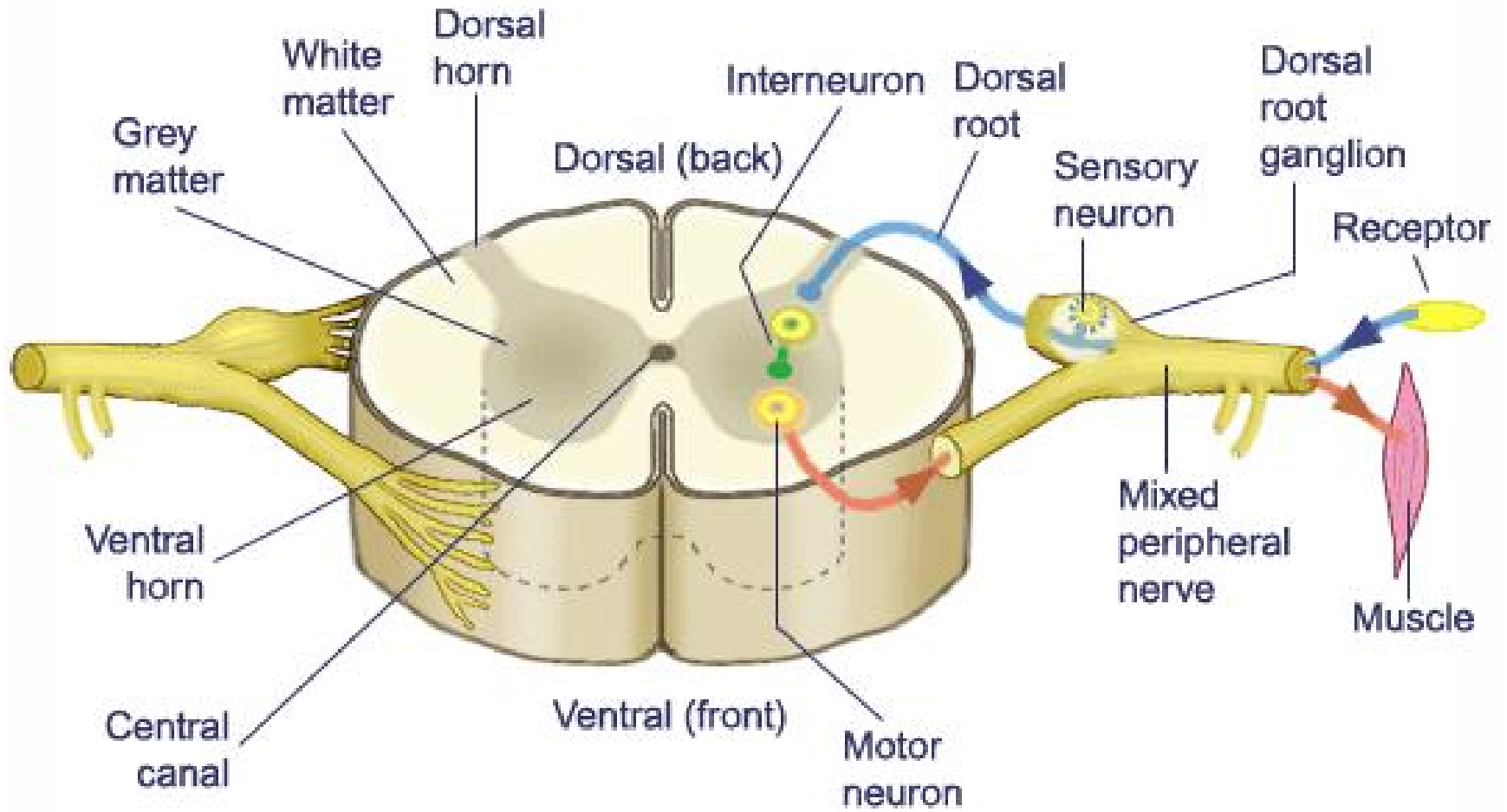
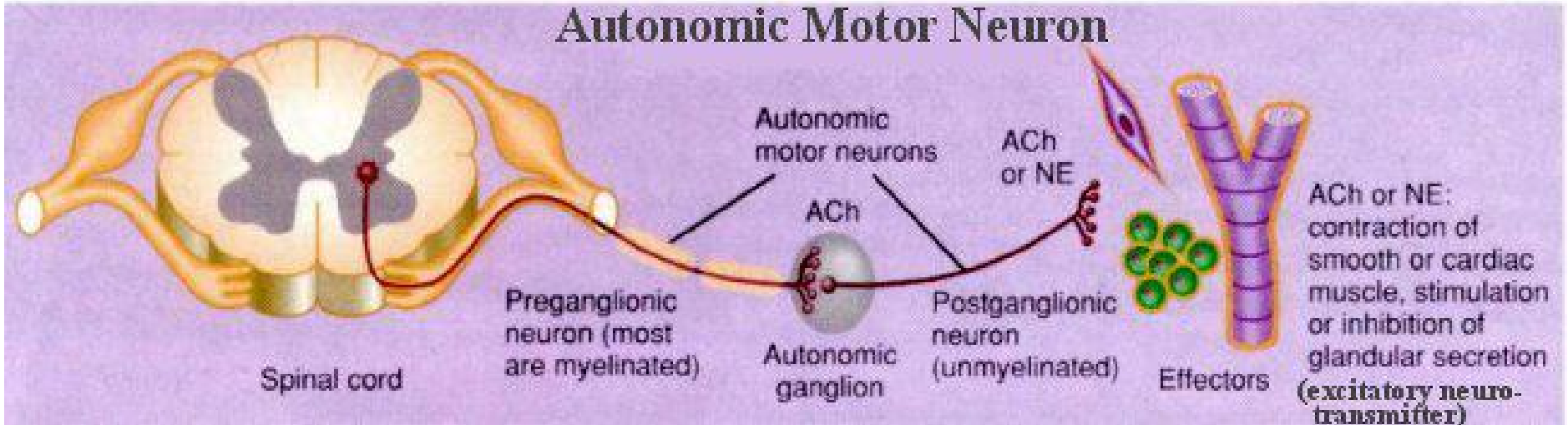
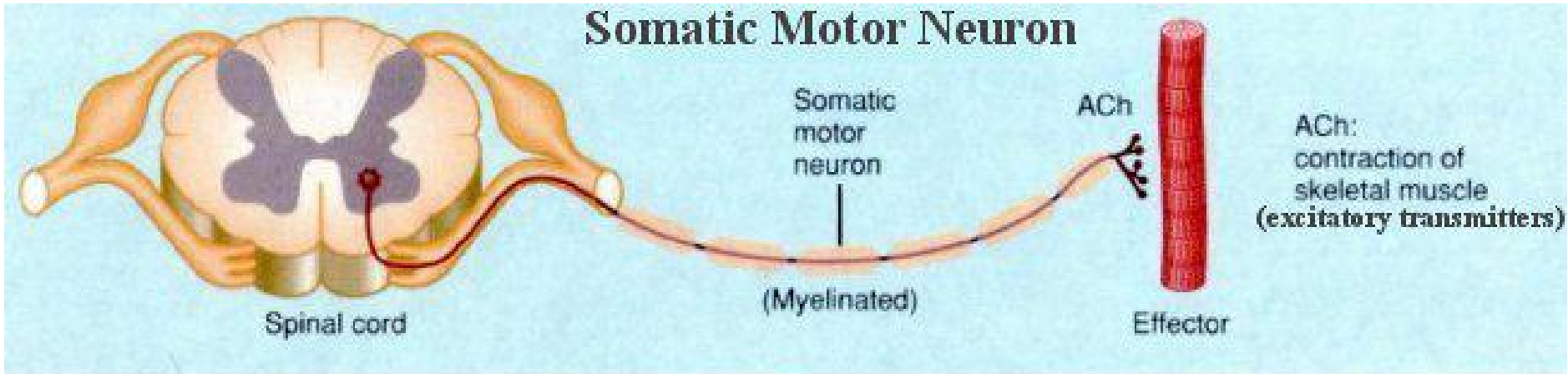


Fig. 1
The organisation of the Nervous System.

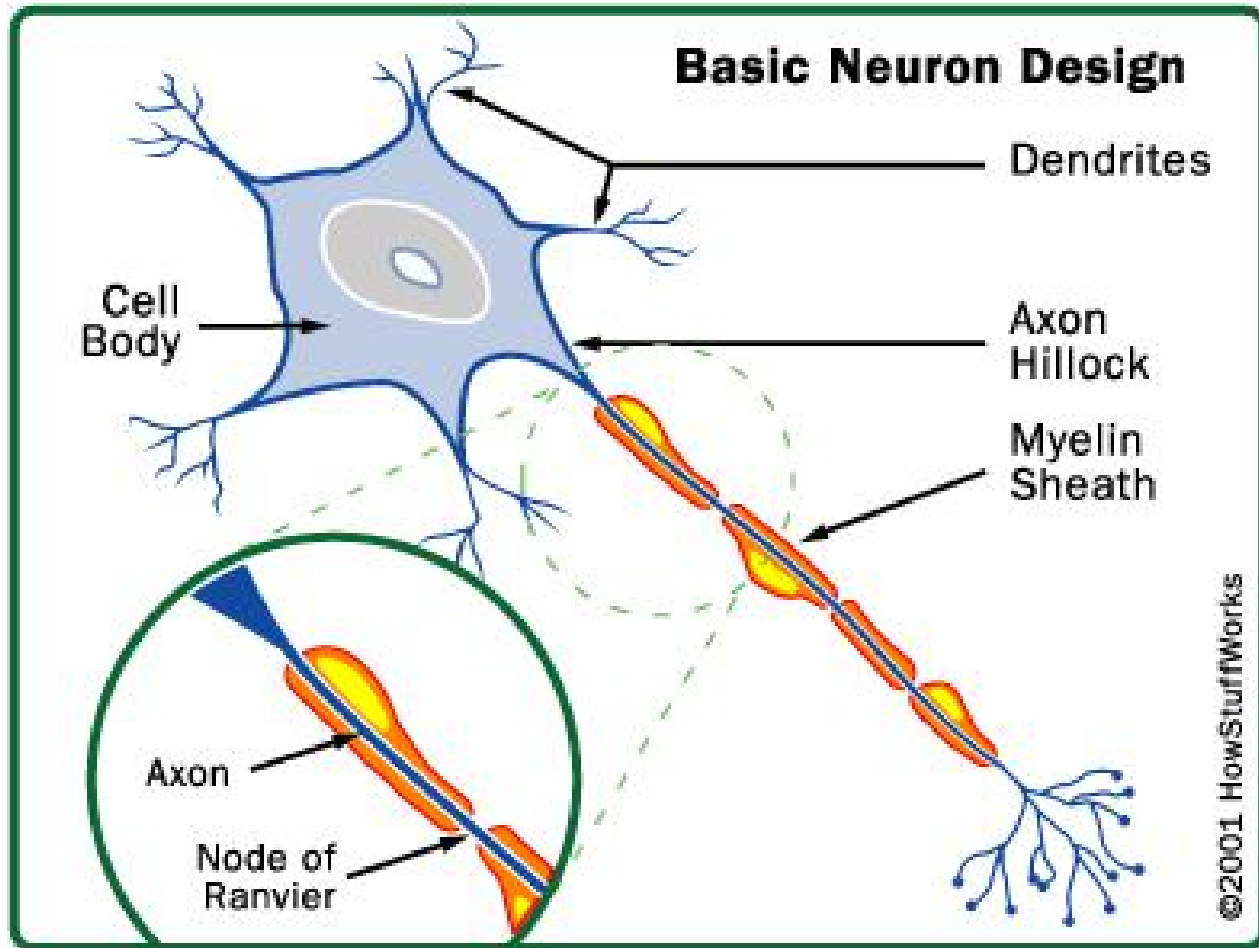
Peripheral nerve



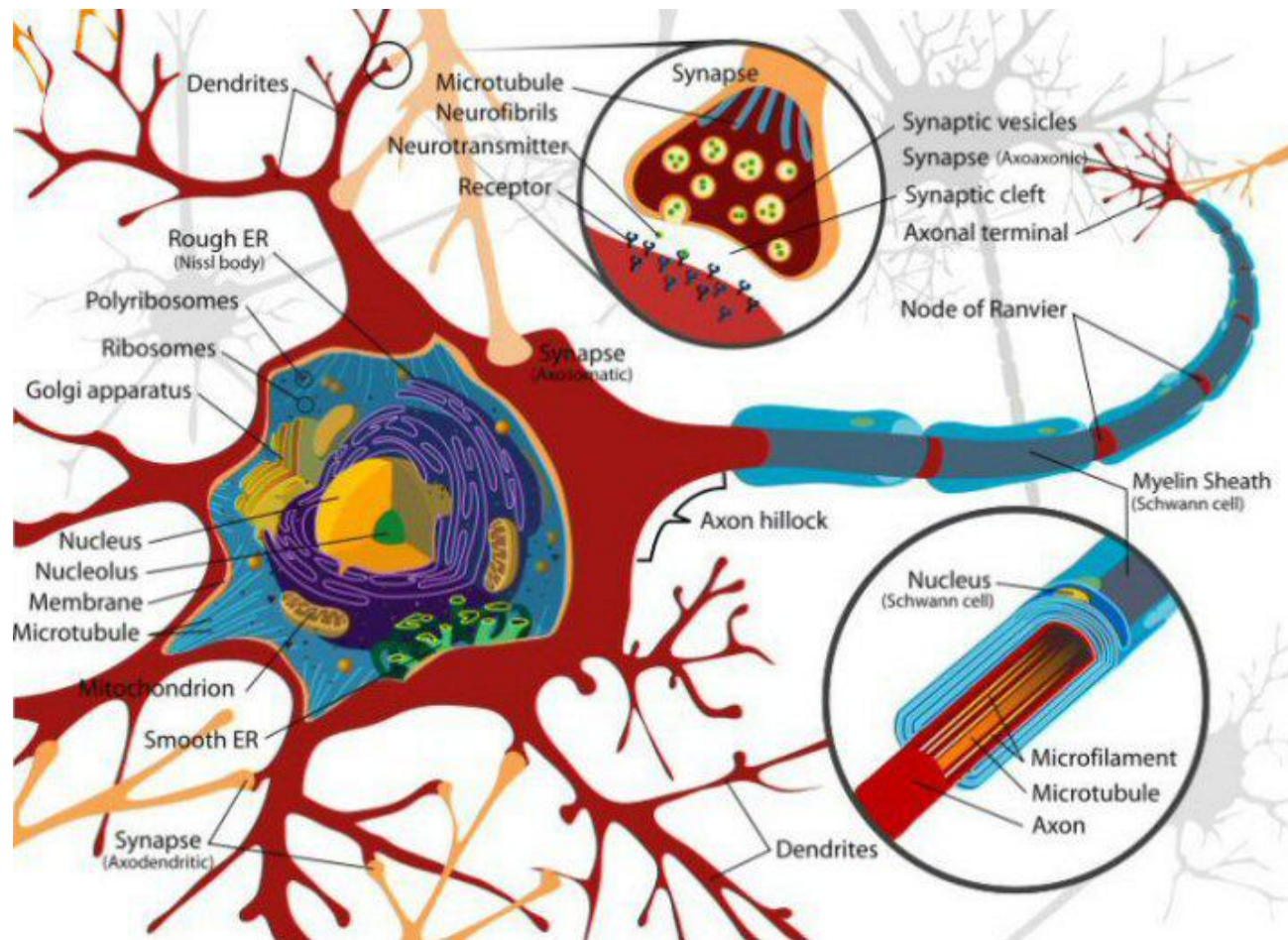
Motor neuron



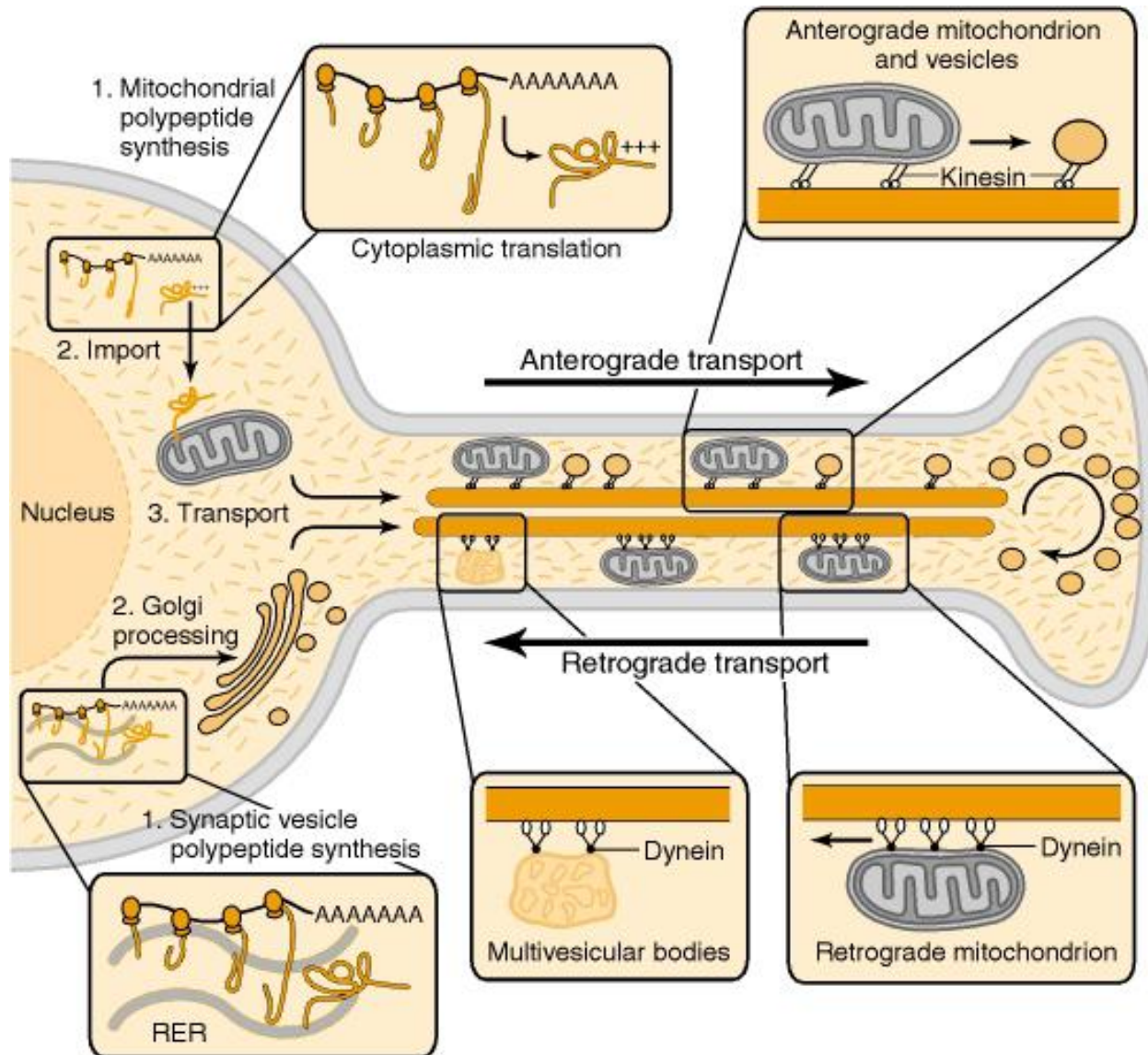
Neuron



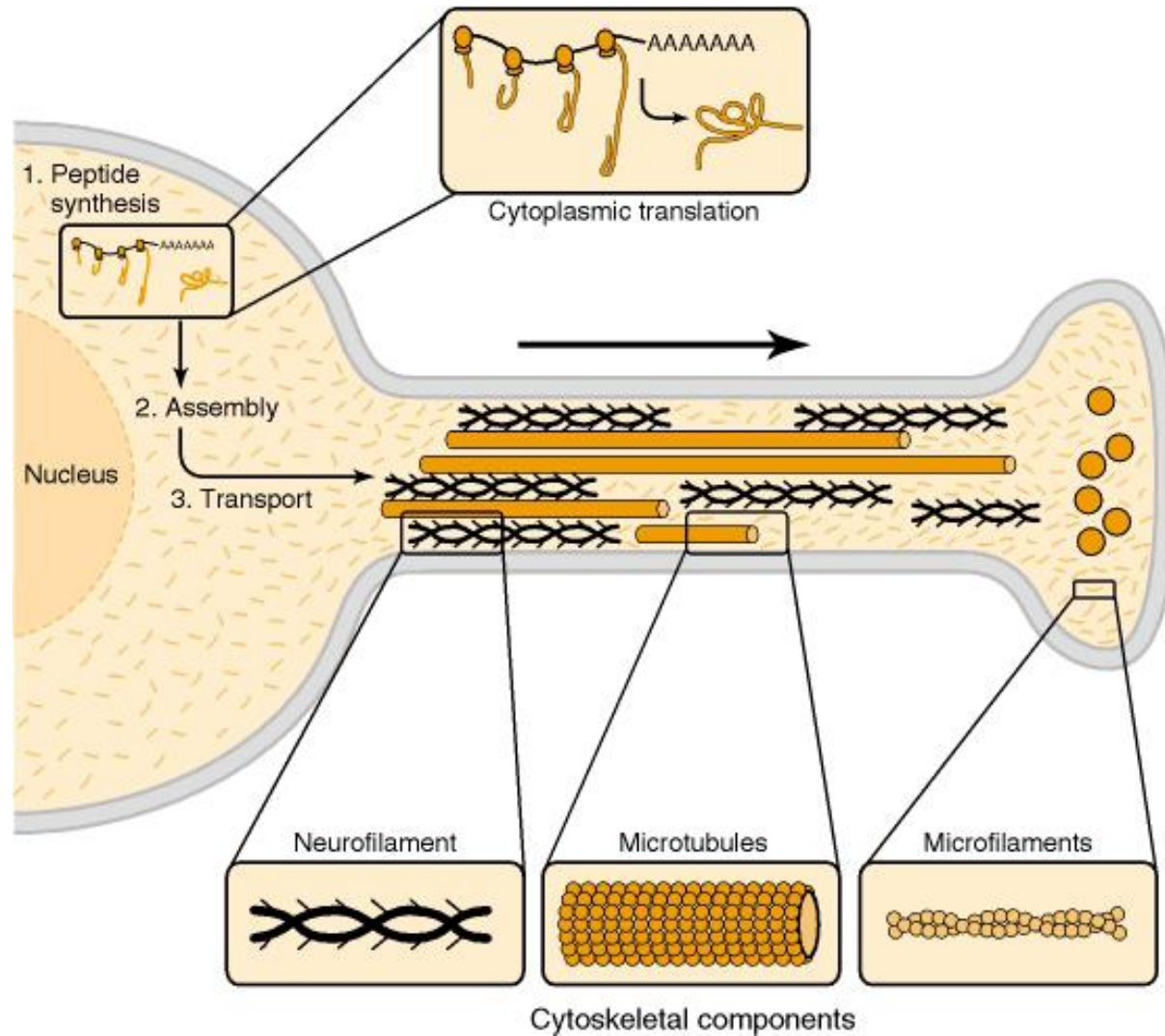
Neuron physiology



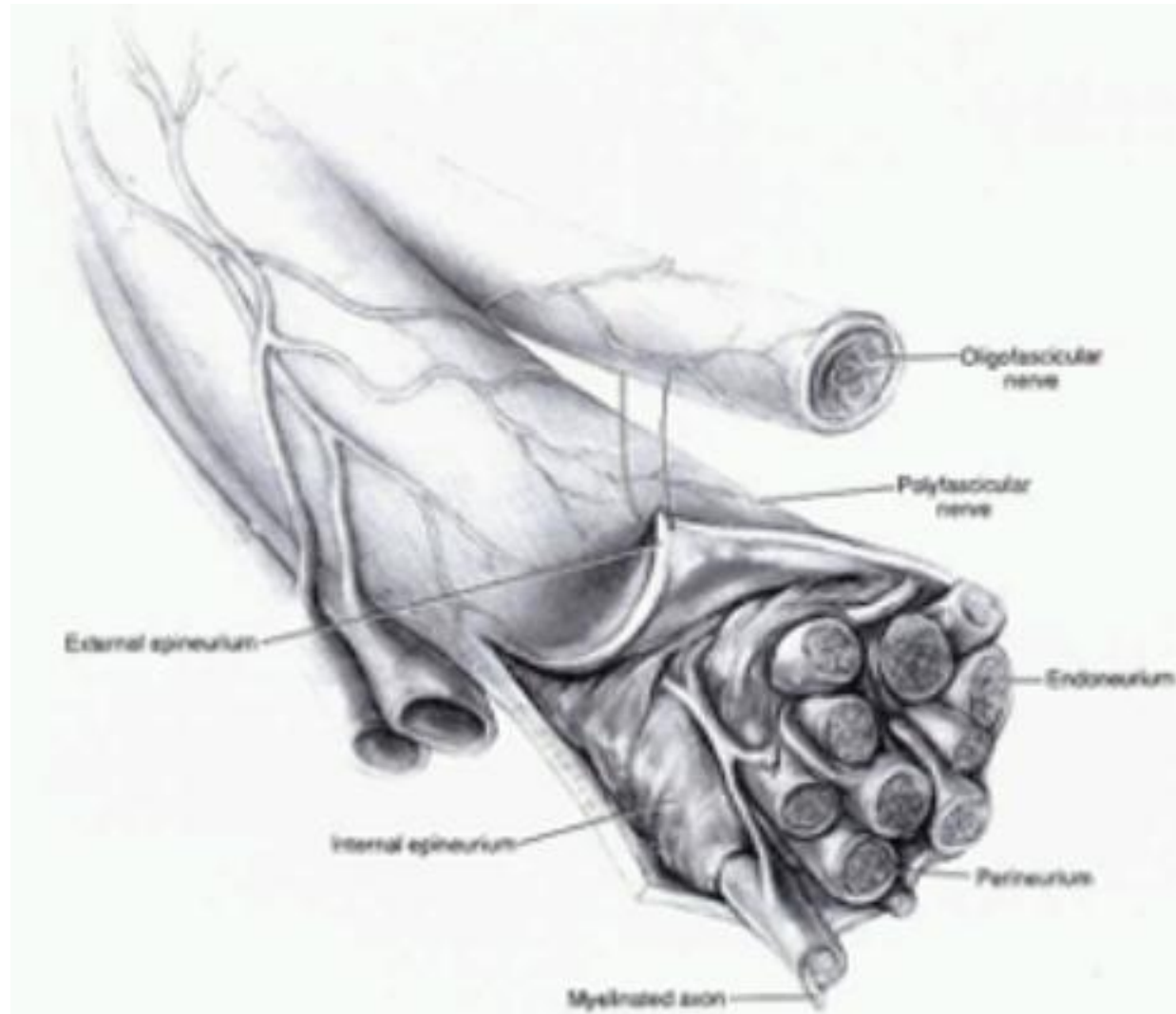
Neuronal transport



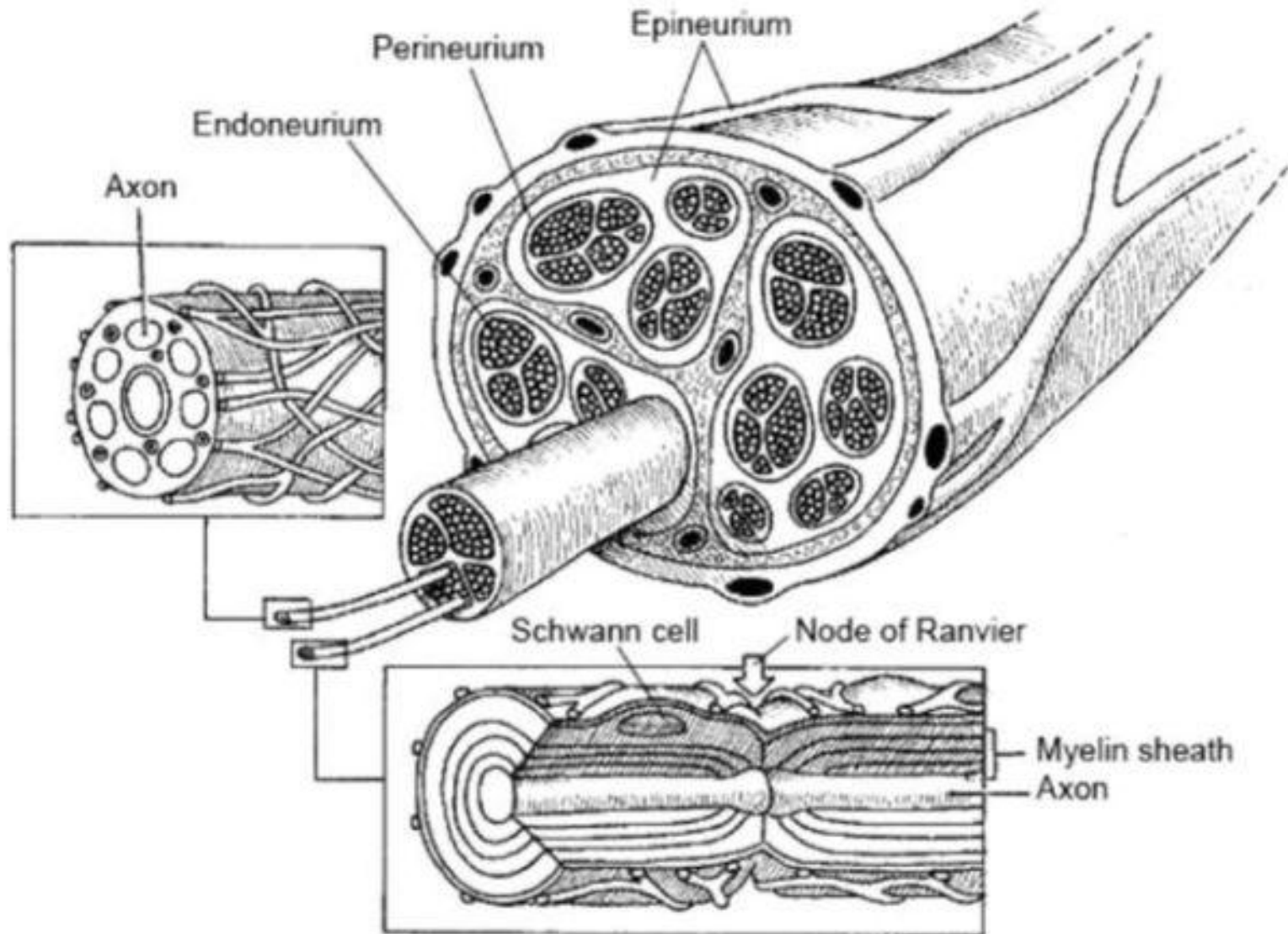
Neuronal transport



Peripheral nerve



Peripheral nerve



Basic Injury Types

1. Stretch-related injuries
 - Brachial plexus avulsion
 - Fracture of humerus
 - Fracture of peroneal head
 - Erb palsy
 - THA (Total hip arthroplasty)
2. Lacerations (created by knife blade)
3. Compression:
 - Saturday Night palsy
 - Disc herniation

Nerve Injury Classification

1. SEDDON: 3 types

- Seddon HJ. “Three types of nerve injury”. *Brain* 66:237–288, 1943

2. SUNDERLAND: 5 types

- Sunderland S. *Nerves and Nerve Injuries*, ed 2. London: Churchill Livingstone, 1978

Peripheral Nerve Injury Classification

Tissue Damage

Recovery

Epineurium

Perineurium

Endoneurium


Axon

Myelin

None

Incomplete

Full



Sunderland Grade

1

2

3

4

5

Seddon Grade

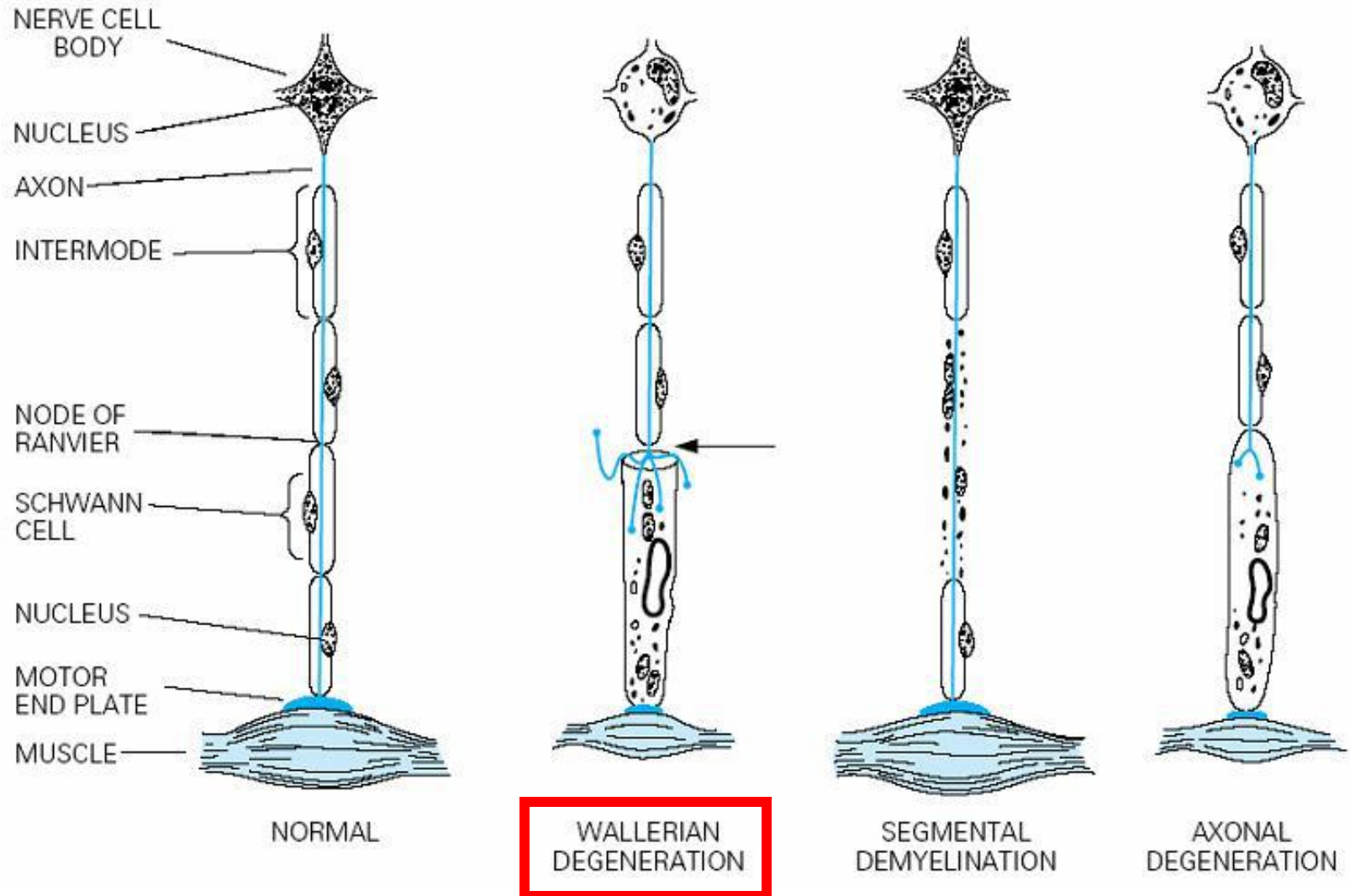
Neurapraxia

Axonotmesis

Neurotmesis

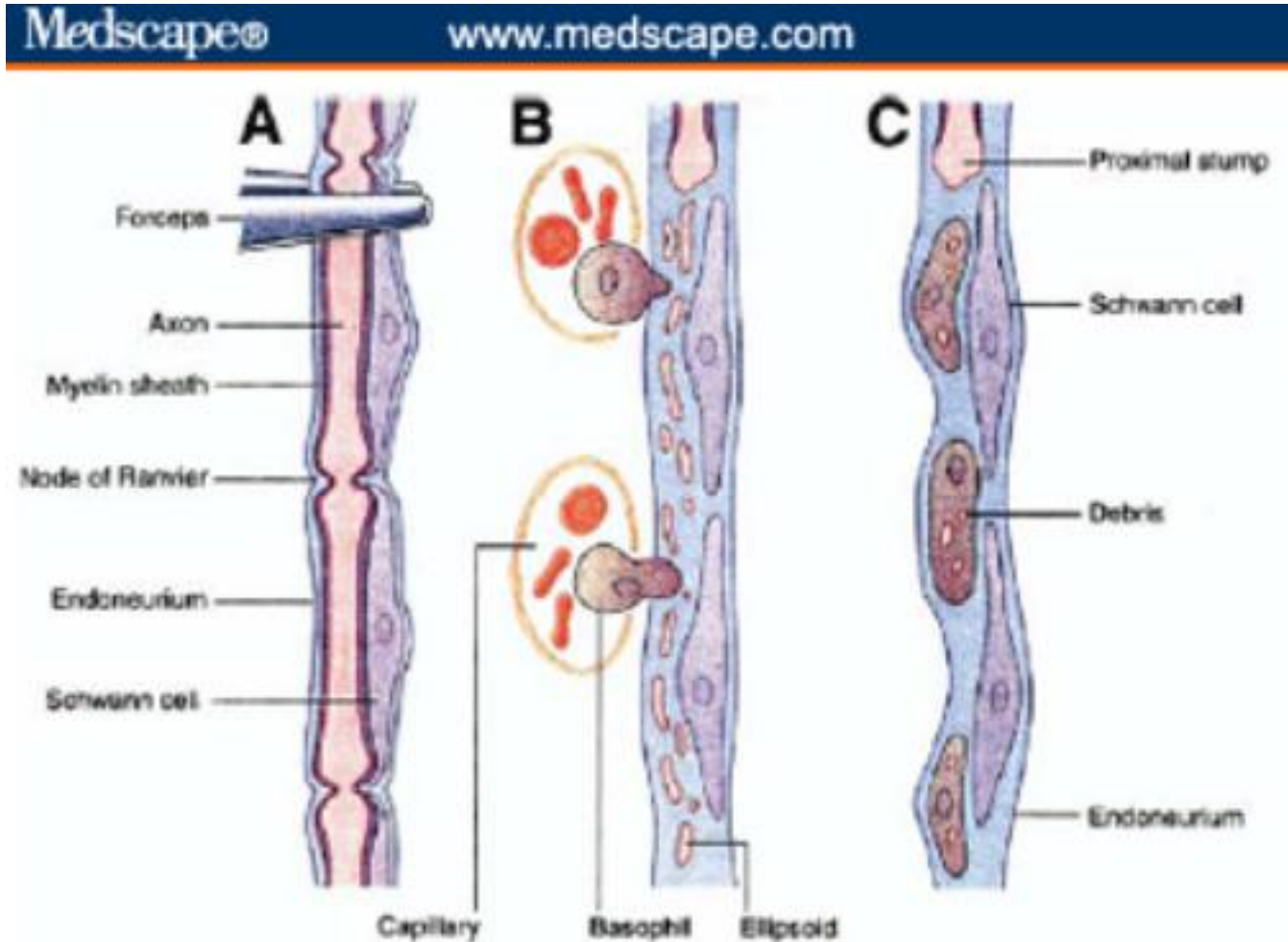
Type and Mechanism	Etiology	Injury Degree	Nerve damage	Recovery
Neurapraxia conduction block	Stretch	Least severe	Axons intact Nerve sheaths intact No Wallerian degeneration	Complete
Axonotmesis nerve damage and axon loss	Compression and/or traction	Moderate	Axons damaged ± Nerve sheath disruption Wallerian degeneration	Partial/full
Neurotmesis severed nerve	Rupture or avulsion	Severe	Axon disruption Nerve sheath disruption Wallerian degeneration	None without surgery

Wallerian degeneration (1850)



Wallerian degeneration:

fragmentation of both axons and myelin → **phagocytosis**



Neural response to injury: degeneration and regeneration

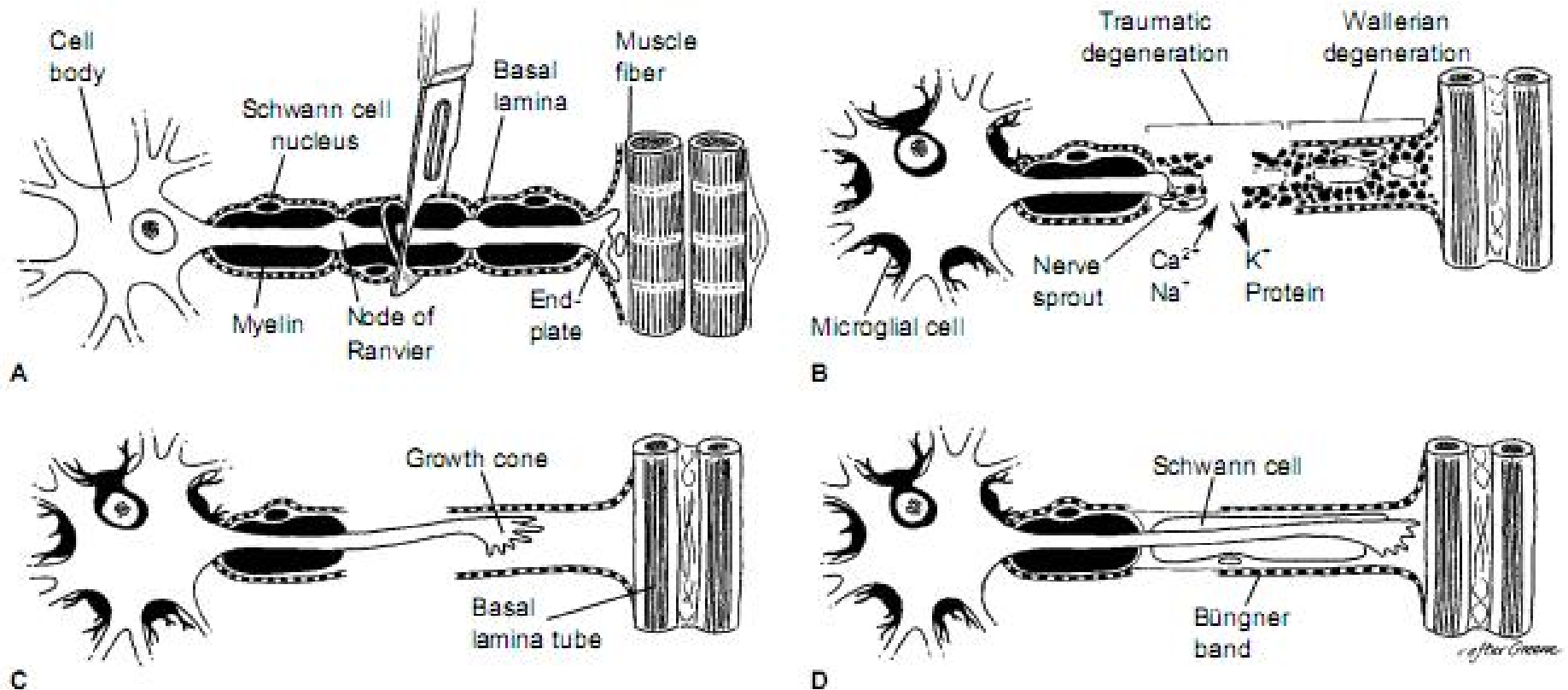



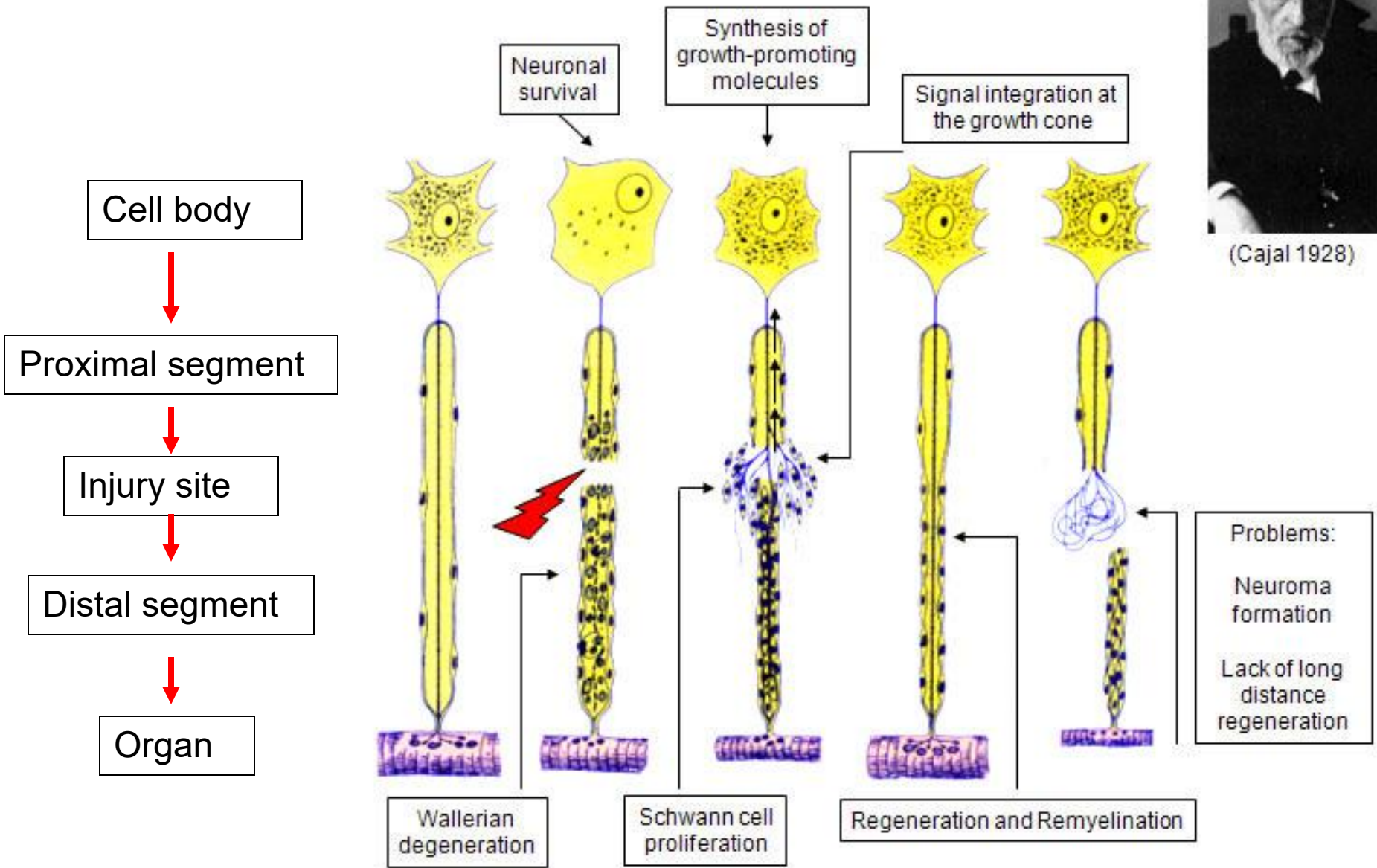
Figure 3 Degeneration and regeneration of the peripheral nerve. A, Transection of the axon. B, Traumatic degeneration in the zone of injury and wallerian degeneration distally. C, Growth-cone regenerating down the basal lamina tube. D, Schwann cells aligning to form Büngner bands. (Adapted from Seckel BR: Enhancement of peripheral nerve regeneration. *Muscle Nerve* 1990;13:785-800. Copyright 1989 Lahey Clinic. Reproduced with permission from John Wiley & Sons, Inc.)

Source: Lee SK et al (2000). "Peripheral nerve injury and repair". *Journal of American Academy of Orthopaedic Surgeons* Vol 8, No 4, 243-252

Peripheral nerve regeneration



(Cajal 1928)



Peripheral Nerve Injury and Repair

Neurorrhaphy

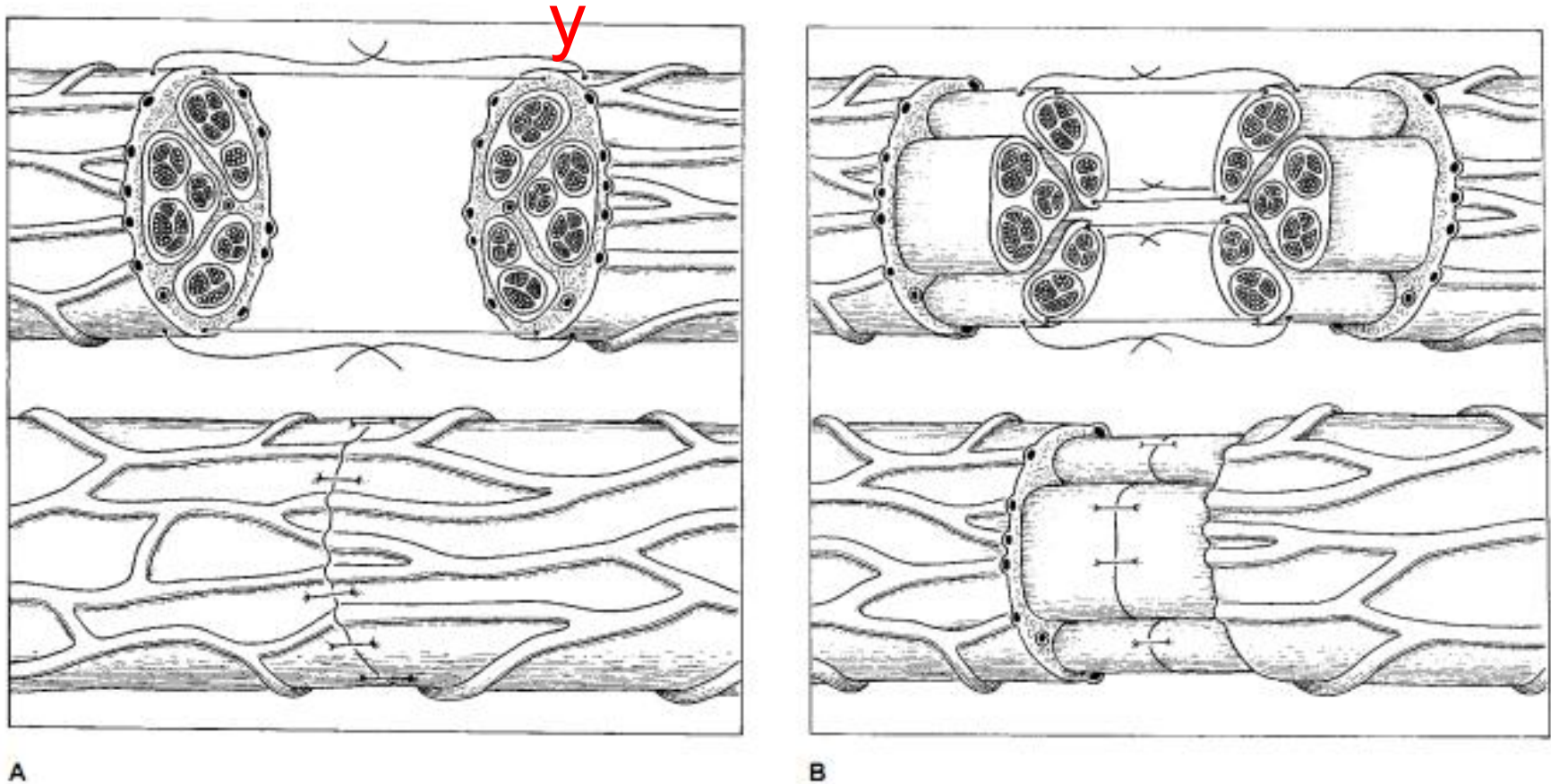


Figure 4 A, Epineurial neurorrhaphy. B, Group fascicular neurorrhaphy. (Adapted with permission from Lundborg G: *Nerve Injury and Repair*. New York: Churchill Livingstone, 1988, pp 199-200.)

Source: Lee SK et al (2000). "Peripheral nerve injury and repair". *Journal of American Academy of Orthopaedic Surgeons* Vol 8, No 4, 243-252

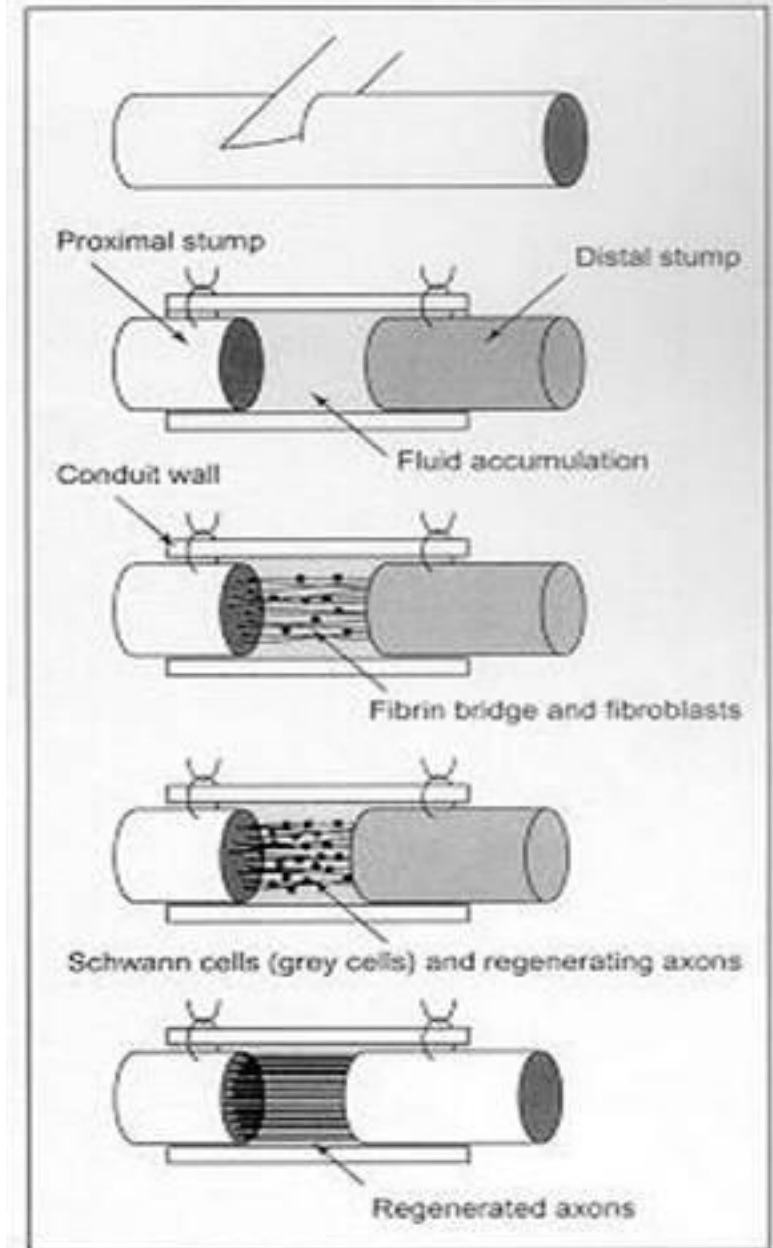
Peripheral Nerve Injury and Repair

Nerve Grafting:

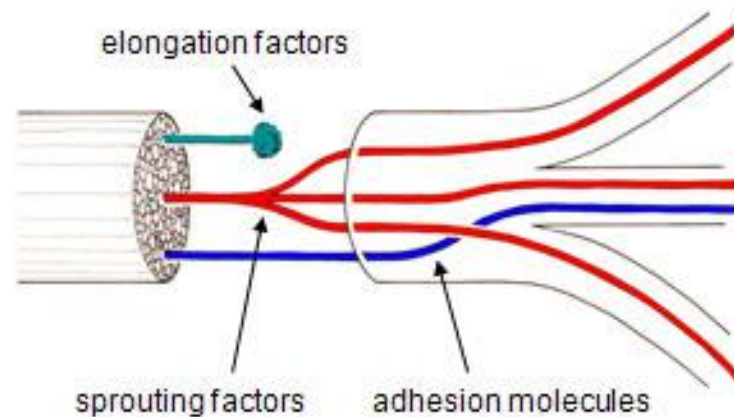
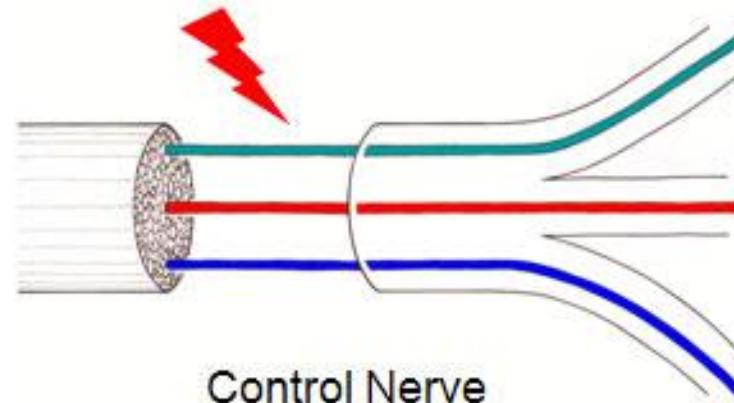
1. Autografts (sural nerve)

2. Allografts

Source: Lee SK et al (2000). "Peripheral nerve injury and repair". *Journal of American Academy of Orthopaedic Surgeons* Vol 8, No 4, 243-252

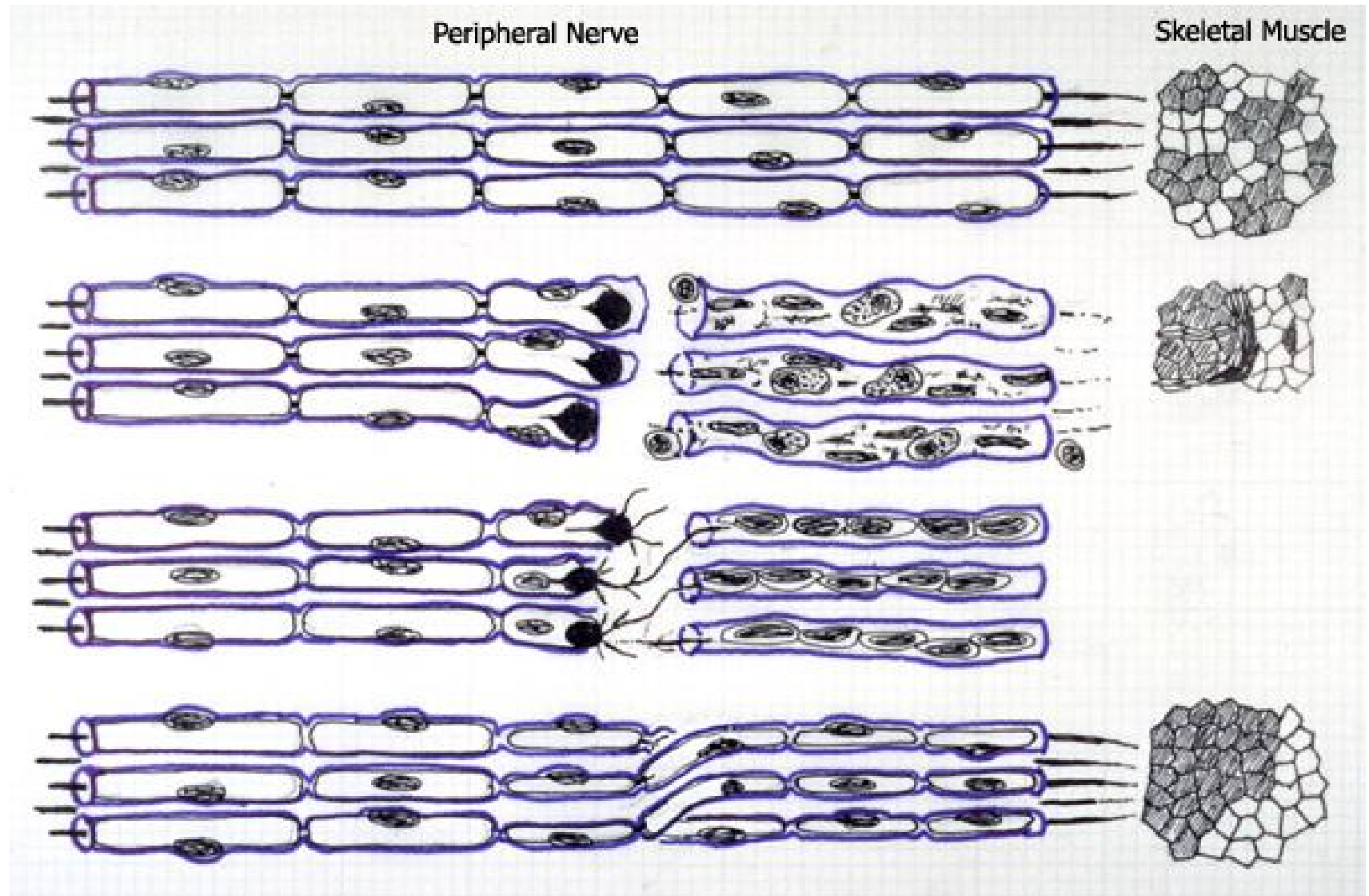


Problems: Growth arrest, axonal sprouting and misdirection in response to a peripheral nerve lesion



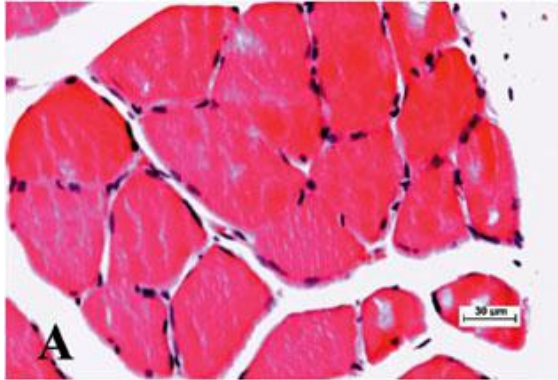
Lesioned Nerve

Misdirected reinnervation

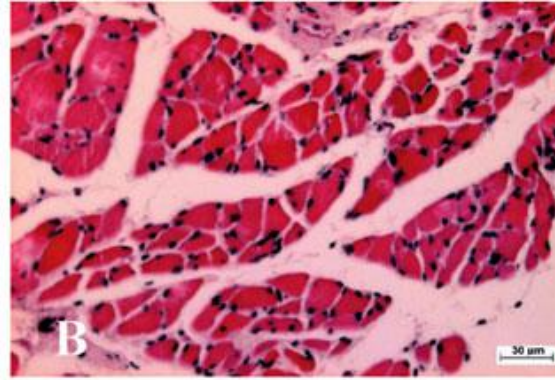


Denervated Skeletal Muscle

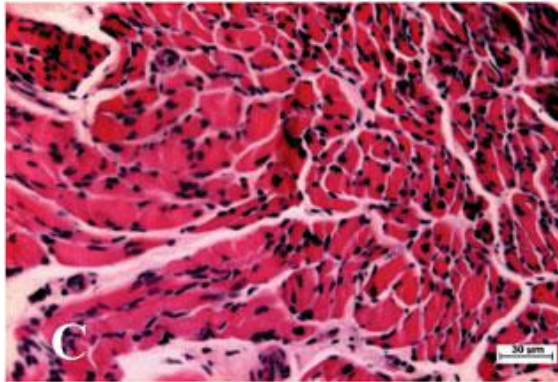
Normal soleus



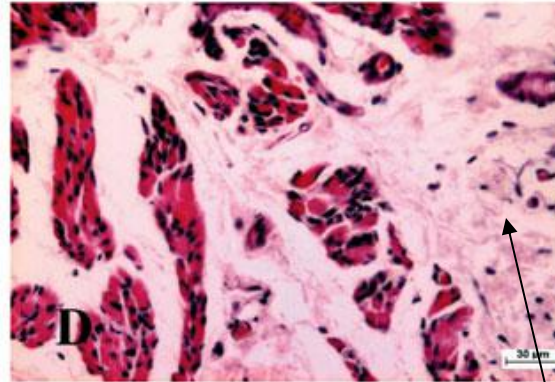
Denervation for 4 weeks



Den. for 10 weeks



Denervation for 15 weeks



Atrophy of the muscle belly

Invasion of connective tissue

Thank you for your attention!